

## Comparative Study of the Effect of Aqueous Mushroom Extract (*Pleurotus tuberregium*) and Pilocarpine on the Schlemm's Canal in Rabbit: A Morphological Study of the Outflow Facility

G.A. Akinlabi\*, Abumere O.O. & Shuaib A.O.  
Department of Optometry, University of Benin. Benin City.

### Abstract

*Pleurotus tuberregium* is a mushroom species that has been shown to reduce intraocular pressure. This study is aimed at finding out the cellular morphological changes that occur in the Schlemm's Canal as it relates to outflow facility due to the administration of *Pleurotus tuberregium* as well as comparing the changes that occur due to Pilocarpine. This study was carried out using 12 New Zealand rabbits which was divided into three groups with four rabbits in each group. Group 1 was administered with the pilocarpine, group 2 was administered with aqueous mushroom extract, (*Pleurotus tuberregium*) and group 3 served as the Control group. Afterwards the animals in each group were sacrificed and their eyes enucleated. The enucleated eyes then went through histopathological investigations with sectioning and preparation of slides. Analyses and capturing of the slides was then done using the light microscope and capturing camera. Sectioning and viewing of the scleral venous sinus or schlemm's canal under a high magnification of x40 and x100 respectively with a light microscope revealed that treatment with pilocarpine and aqueous mushroom extract resulted in the formation of an increased number of vascular channels and also increased tortuous and convoluted nature of these channels, with a slightly greater effect in aqueous mushroom treated cells.

**Conclusion:** mushroom extract causes increased tortuous and convoluted nature of vascular channels. This tortuosity leads to an increase in the sinus spaces or vacuoles which then leads to an increase in the outflow facility and a resultant decrease in the intraocular pressure.

**Keywords:** *Pleurotus tuberregium*, Schlemm's canal, Pilocarpine

### Introduction

Two main structures are involved in the movement of aqueous which are the ciliary body and trabecular meshwork<sup>1</sup>. Aqueous humor leaves the eye through two pathways. The conventional pathway involves aqueous humor passing through the trabecular meshwork, across the inner wall of Schlemm's canal, into its lumen, and then draining in to the collector channels, aqueous veins and episcleral veins<sup>2</sup>. The movement of fluid through the convectional pathway occurs down a pressure gradient from the Trabecular Meshwork into Schlemm's canal and through the inner wall of Schlemm's canal<sup>1</sup>. Unconvectional outflow does not contribute significantly to aqueous outflow in normal eye<sup>3</sup>. A rise in IOP or a weakening of the trabecular meshwork results in a distension of the trabecular meshwork and a change in the Schlemm's canal, this in turn would generate a very high outflow resistance. If debris builds up, due to infection or injury in the aqueous humor, the canal is blocked and ocular hypertension is the result<sup>4</sup>.

Morphological studies on the effects of pilocarpine on the outflow system with respect to the Schlemm's canal have been carried out on both animals and man<sup>5,6</sup>. Evidence has shown that there is a difference in the morphological changes that occur in the Schlemm's canal due to the effect of topical pilocarpine in different species<sup>6,7,8,9</sup>. Pilocarpine causes distension of endothelial meshwork, and also increases the number of giant vacuoles in the lining endothelium of Schlemm's canal<sup>6</sup>.

Mushrooms are sometimes referred to as plants, but they are different from plants in that they lack the green pigment that all plants have which is called chlorophyll. They are therefore placed into a kingdom of their own, the Kingdom of fungi<sup>10</sup>. Mushrooms have been found useful not only as a food source but also for its medicinal value<sup>11</sup>. There have been countless instances where extracts from plants, mushroom specifically have been proven beneficial in either alleviating or completely stilling the course of different diseases<sup>10,12,13,14</sup>.

Mushrooms have been shown to have a significant effect on the intraocular pressure in animals. Akinlabi et al.<sup>14</sup> carried out a study to determine the effect of mushroom extract and timolol maleate on dexamethasone induced ocular hypertension in feline's eye model. In this study it was discovered that topical instillation of mushroom extract significantly reduced IOP in dexamethasone treated cats, when compared with timolol and control. The exact mechanism of action of mushroom extract has at yet not been fully understood. This is therefore, the significance of this study in relation to the morphology of the Schlemm's canal.

\*Corresponding Author's E mail: [gaakinlabi@hotmail.com](mailto:gaakinlabi@hotmail.com)

## Materials and Method

**Extract preparation:** unadulterated fresh PT mushrooms were got from the Department of Plant Biology and Biotechnology garden, University of Benin, Benin City, Nigeria. The mushrooms were dried, grinded to powder form and 500g macerated in 3liters of distilled water for 48h and then filtered thrice through a clean white cloth. The result which was milky white extract was then dried for four days in an oven set at 40°C to give a yield of 6.1% w/w of the starting material.

**Animals:** A total of twelve (12) experimental rabbits were used for this study. The rabbits included in the study were those with no clear signs of diseases, systemic and ocular and no clear signs of head trauma. Those that showed signs of diseases and head trauma were excluded. The rabbits were divided into three different groups with one of the groups serving as a control, another treated with aqueous mushroom extract and the last treated with pilocarpine. The 12 rabbits, weighing between 1.3kg and 2.0kg were divided into three test groups with four animals in each group. The animals were well fed with animal food and clean water; their cages properly cleaned every day to avoid infections. They were kept in order for them to acclimatize to their new environment for one week before the commencement of the experiment.

The animals then received topical application of one of the two treatments, two times daily for two weeks;

- Group A : received 2% pilocarpine
- Group B : received aqueous mushroom extract
- Group C : control

At the end of two weeks, the animals were then taken to University of Benin teaching hospital (UBTH) where the enucleation was performed.

### Isolation of tissue

The eyes of the animals were enucleated with the aid of the diagnostic set. The animals were first anaesthetized with 0.5% chloroform before enucleation was done in order to preserve the viability of the tissues. The eyes were then fixed in buffer solutions for 24 hours. Sectioning of each eye ball transversely in order to expose the tissue for examination was done. When the right tissue was got, it was cut out of the eye ball for the next stage. After which the tissues were processed; which further included fixation, dehydration, impregnation, embedding in paraffin wax to allow for solidification, sectioning and staining.

Images from the slides were used to analyze the result using a light microscope and a caption camera. The microscope used was the Olympus AXL LAPO with magnification ranging from x10, x40 and x100. The capturing camera used was the Samsung digital camera, 12mega pixels sv20. The analysis was carried out at the Department of Anatomy, University of Benin.

## Results and Discussion

It was observed that in the group instilled with pilocarpine, more vascular channels were formed when compared to the control. There was also a relative increase in the tortuous and convoluted nature of the vessels. The vascular channels of those treated with aqueous mushroom extract were even more tortuous and convoluted than those found in the pilocarpine treated cells. This increase in tortuosity further resulted in the presence of larger sinus spaces or vacoules. The cells in the connective tissue core were more prominent and more pigmented in the cells treated with aqueous mushroom extract than those treated with pilocarpine.

Sinuses generally are found in various organs of the human system, for example, the heart. They are linked to the veins and they undergo venous dilation which results in the drainage of a large amount of blood and fluid which helps to regulate the blood pressure.

When the scleral venous tissues of the treated was compared with the scleral venous tissues of the control, it was observed that the histological structure of the schlemm's canal in eyes of rabbits treated with pilocarpine, was different from the normal as seen in the control (Figs. 1&2), more vascular channels were formed. The evidence gotten from the cells treated with pilocarpine was not totally unexpected as several researches both on animals and humans have come up with similar evidence<sup>5,6</sup>. These evidences therefore suggests that an increase in the number and widening of the sinus spaces or vacuoles in the schlemm's canal is an important factor in increasing outflow facility which helps to bring about a reduction in intraocular pressure.

Pilocarpine causes contraction of the ciliary muscle by acting on the M<sub>3</sub> receptors on ciliary smooth muscle cells<sup>9</sup>. When the ciliary muscle contracts the anterior part of the muscle thickens, and the meshwork moves toward the anterior chamber, making the meshwork packing looser. The widening of the spaces between the sheets in the meshwork increases the outflow facility<sup>15</sup>.

Finally, on treatment with aqueous mushroom extract, even more deviation from the normal was seen. It was observed that the vascular channels were even more tortuous and convoluted than those found in the pilocarpine treated cells. This increase in tortuosity further resulted in the presence of larger sinus spaces or vacoules. No

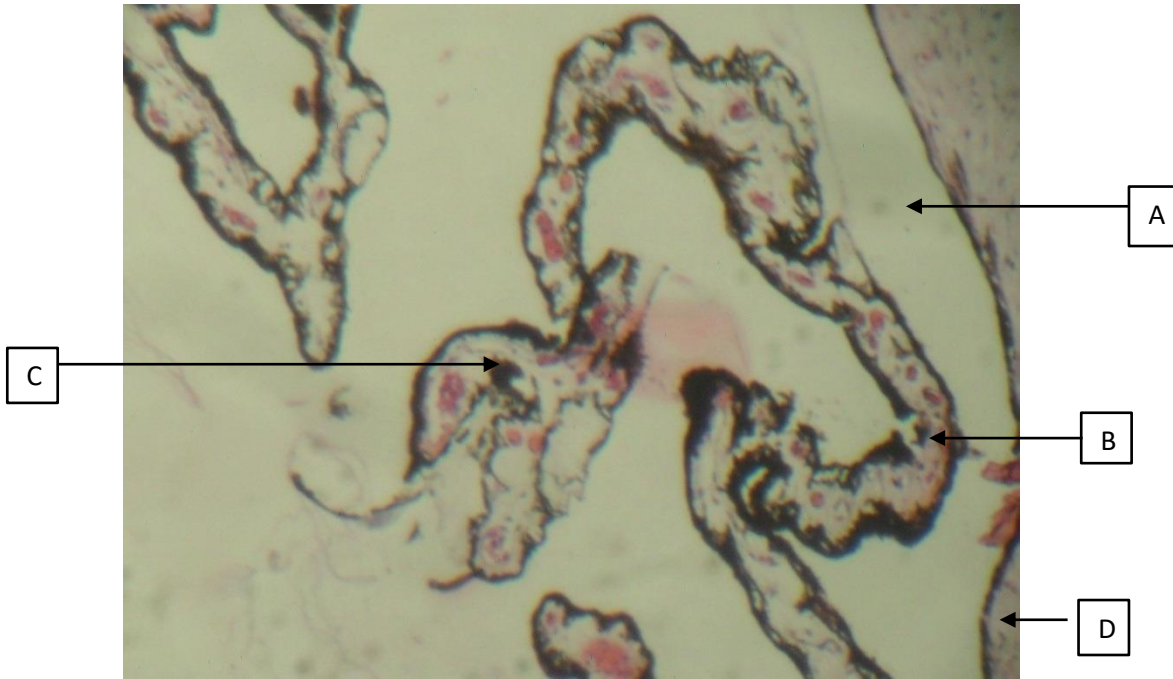


Fig.1. Control: Rabbit eye (Schlemm's canal) composed of A) sinuses B) vascular channels lined by endothelium C) perforated by vascular spaces and D) adjacent connective tissue (H&E x 40)

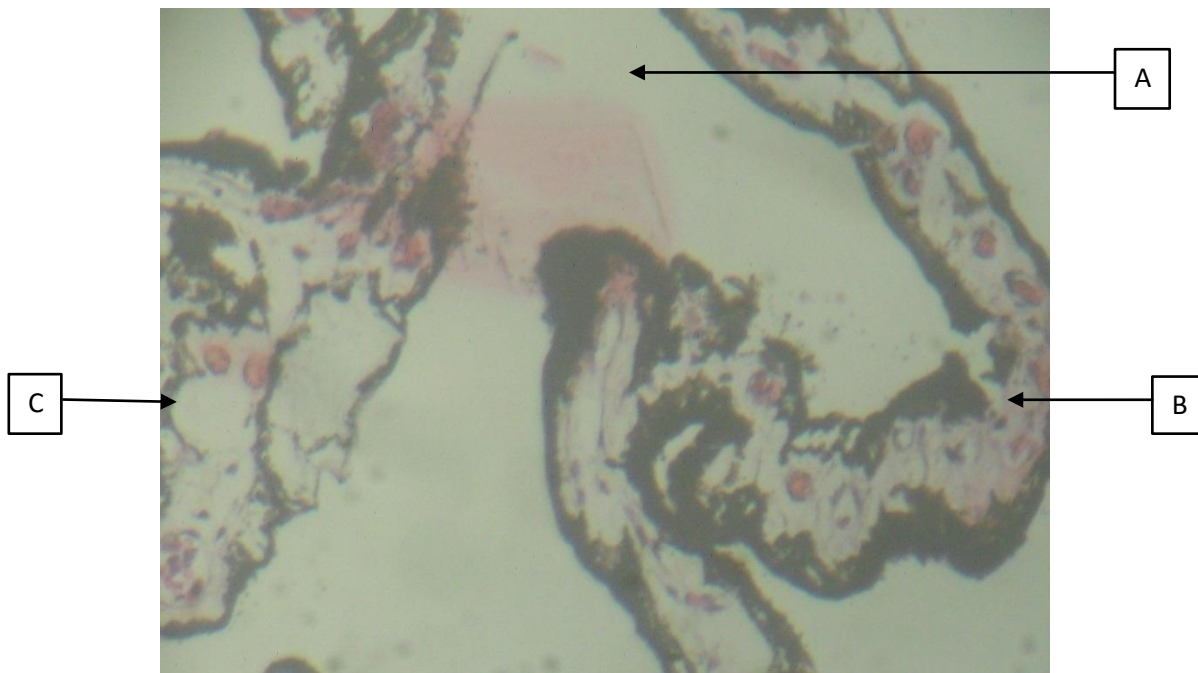


Fig 2: Control: Rabbit eye (Schlemm's canal) composed of A) sinuses, B) vascular channels lined by endothelium, C) perforated by vascular spaces and D) adjacent connective tissue (H&E x 100).

These figures portray the morphology of the scleral venous sinus in a normal state and in the absence of diseases or drugs.

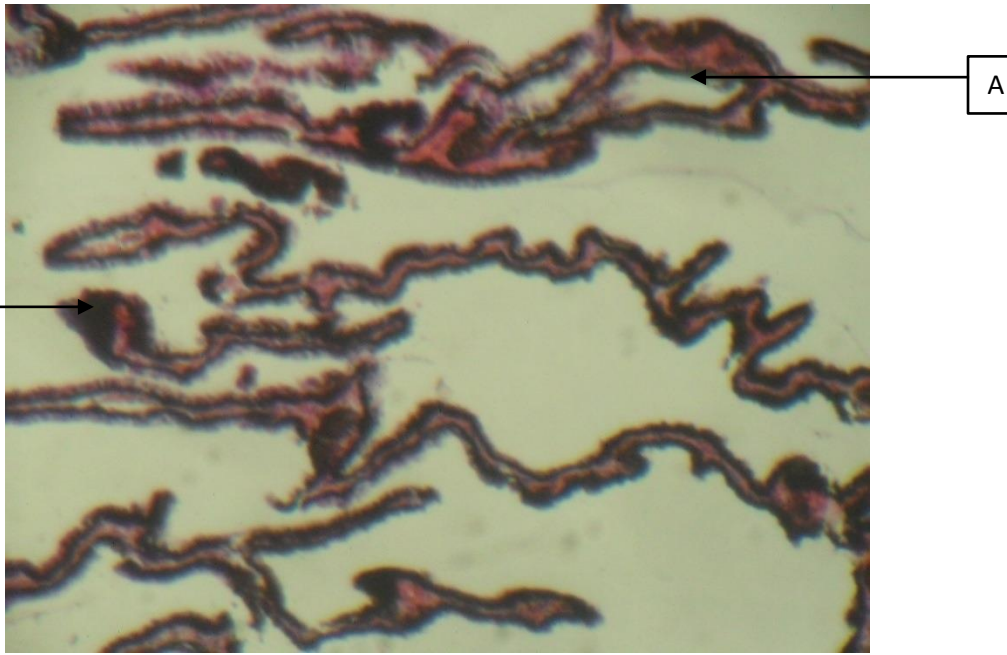


Fig. 3: Rabbit eye (Schlemm's canal) treated with Pilocarpine showing A), increased tortuosity of the vascular channels (mildly tortuous) and B) hyperplastic endothelial lining (H&E x 40)

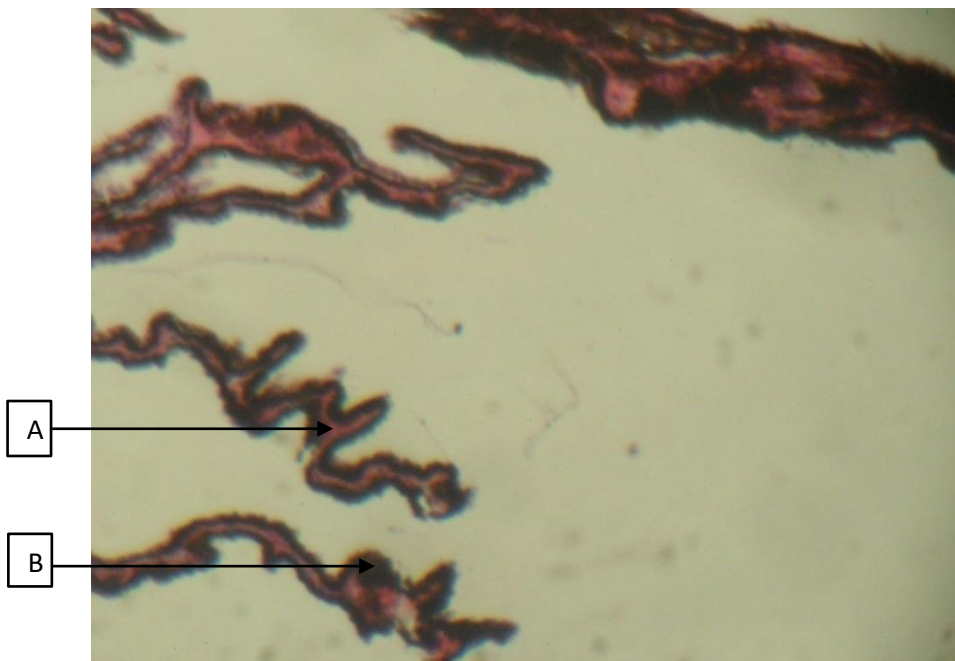


Fig. 4: Same as above (Fig 3) A, B (H&E x 40)

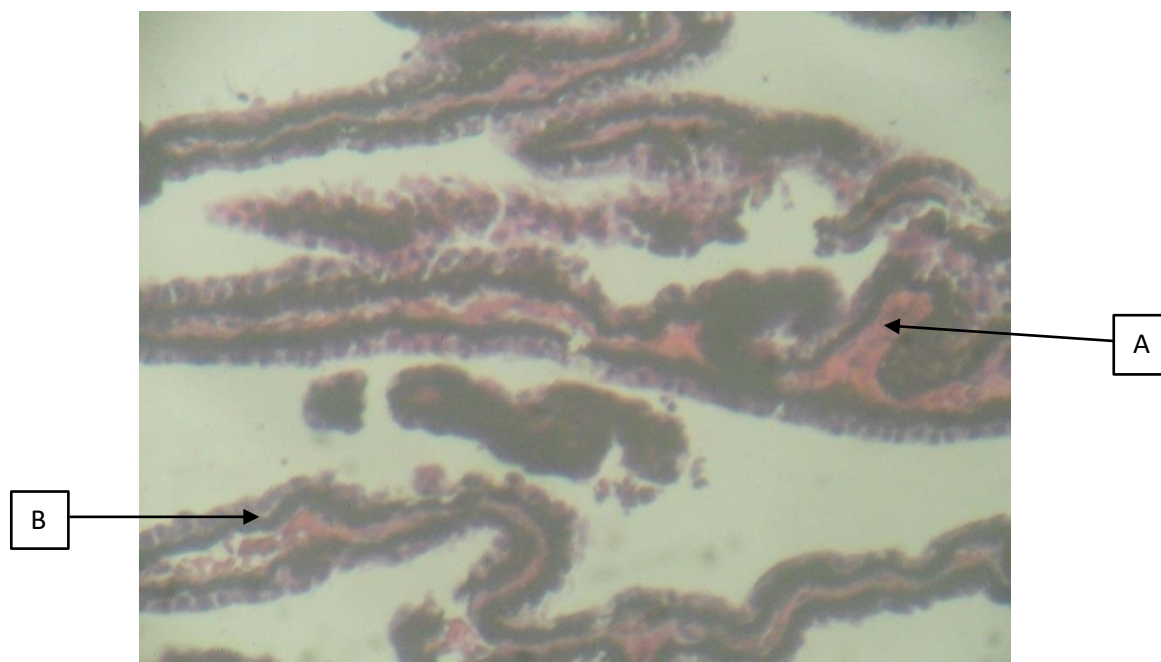


Fig. 5: Rabbit eye (Schlemm's canal) treated with Pilocarpine showing A), increased tortuosity of the vascular channels (mildly tortuous) and B) hyperplastic endothelial lining (H&E x 100).

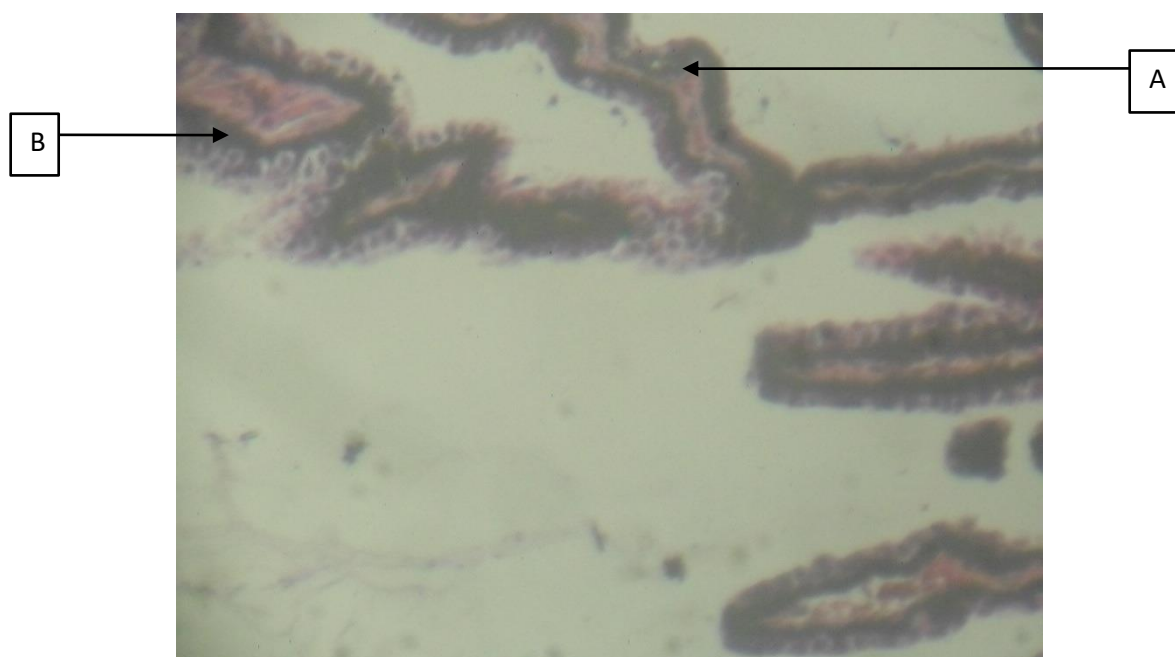


Fig. 6: Same as above (Fig 5) A, B (H&E x 100) This increased magnification further helps to highlight the plumpness and distended nature of the endothelial lining which is an evidence of increased tortuosity of d vascular channels.

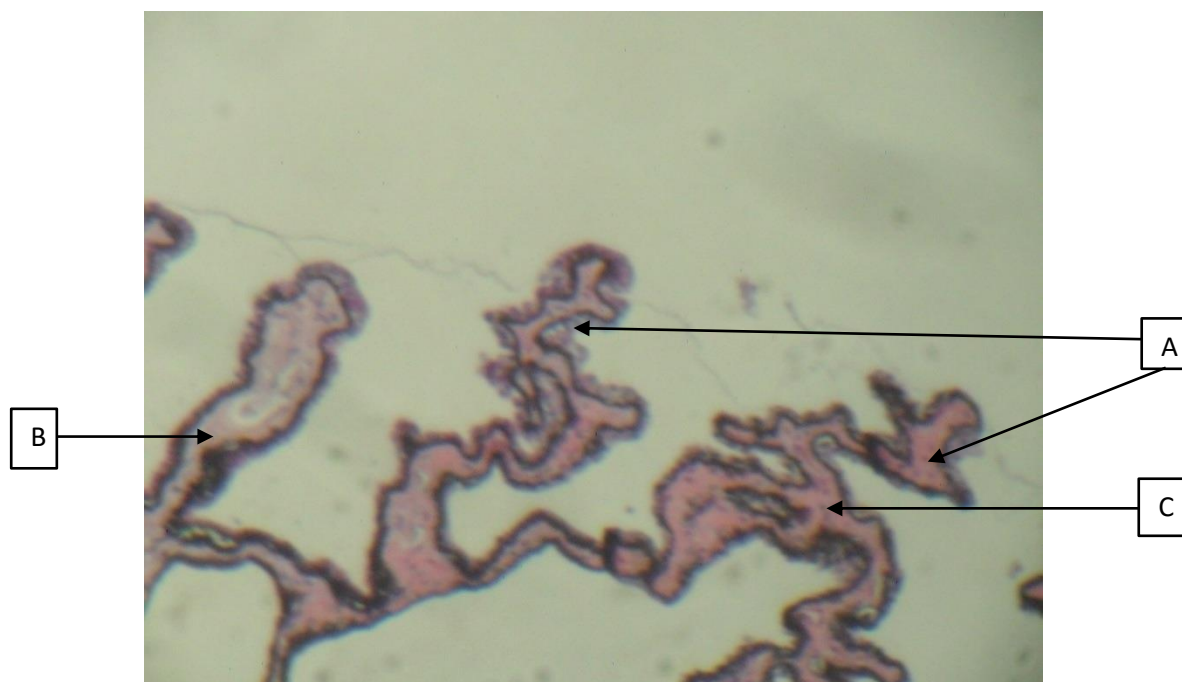


Fig. 7: Rabbit eye (Schlemm's canal) treated with Mushroom extract showing A) moderately tortuous vascular channels, B) mildly hyperplastic endothelial cells and C) thickened connective tissue core (H&E x 40).

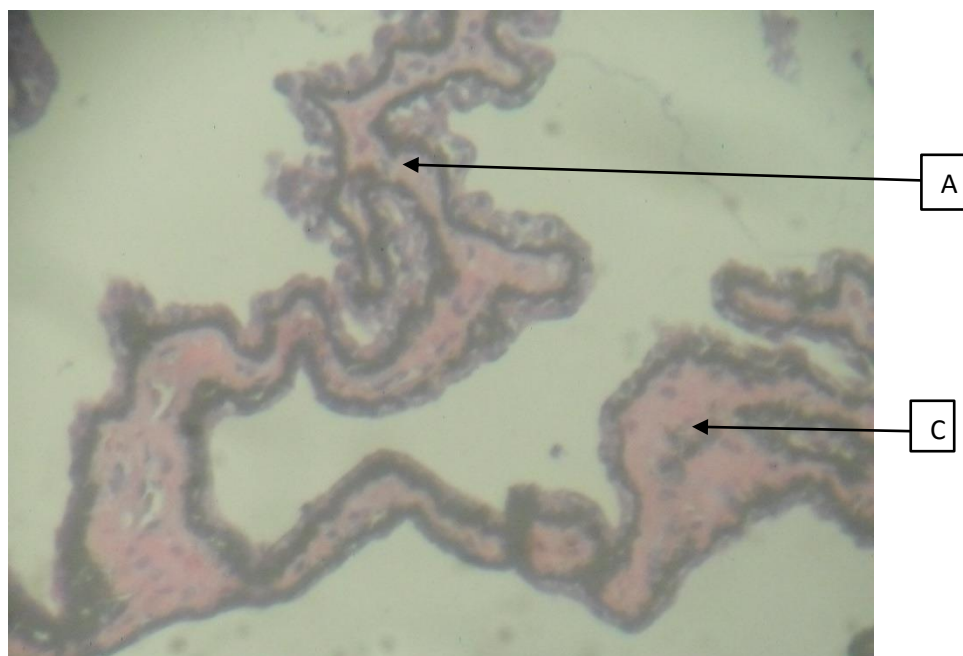


Fig. 8: Same as above (Fig 7) A, C

studies have been carried out on the morphological effect of mushroom extract on schlemm's canal; however, it has been shown to have a contractile effect on iris muscle<sup>16</sup>.

This study shows that mushroom extract might have similar mechanism of action with pilocarpine. The increased tortuosity which resulted in the presence of larger sinus spaces or vacuole suggests that the mushroom extract would be slightly more effective in the reduction of intraocular pressure than pilocarpine.

From previous literatures and the results gotten from his research, it would suggest that due to the slightly greater effect aqueous mushroom extract has on the tissue of the schlemm's canal over pilocarpine, with more emphasis laid on the size of the sinus spaces, aqueous mushroom extract would be slightly more effective in the reduction of intraocular pressure than pilocarpine. It was also observed that the cells in the connective tissue core are more prominent and more pigmented in the cells treated with aqueous mushroom extract than those treated with pilocarpine. The increased pigmentation is most likely just the cell's way of highlighting the prominence of the increased cells present in the connective tissue core.

## References

1. Goel M, Picciani RG, Lee RK, Battacharya SK. Aqueous humor dynamics: a review. *Open ophthalmol Jour*, 4, pp.52–9. 2010
2. Johnson M & Tamm ER. Biomechanics of Aqueous Humor Outflow Resistance\*. *Encyclopedia of the Eye*, pp.173–182. 2010
3. Johnson M. What controls aqueous humour outflow resistance? *Exp Eye Res*, 82(4), pp.545–557. 2006
4. Johnson MC & Kamm RD. The role of Schlemm's canal in aqueous outflow from the human eye. *Invest Ophthalmol Vis Sci*, 24(3), pp.320–325. 1983.
5. Grierson I, Lee WR & Abraham S. Effects of pilocarpine on the morphology of the human outflow apparatus. *Br J Ophthalmol*, 62, pp.302–313. 1978
6. Grierson I, Lee WR & Abraham S. Morphology of the Outflow Apparatus of the. *Investigative Ophthalmol Vis Sci*, 18, pp.346–355. 1979.
7. Lutjen-Drecoll E, Wiendl H & Kaufman PL. Acute and chronic structural effects of pilocarpine on monkey outflow tissues. *Trans Am Ophthalmol Soc*, 96, pp.171–175. 1998.
8. Li G, Farsiu S, Chiu SJ, et al. Pilocarpine-induced dilation of Schlemm's canal and prevention of lumen collapse at elevated intraocular pressures in living mice visualized by OCT. *Invest Ophthalmol Visl Sci*, 55(6), pp.3737–3746. 2014.
9. Overby DR, Lutjen-Drecoll E, Stamer D, et al. The structure of the trabecular meshwork, its connections to the ciliary muscle, and the effect of pilocarpine on outflow facility in mice. *Invest Ophthalmol Visl Sci*. 55(6), pp.3727–3736. 2014.
10. Feeney MJ, Dwyer J, Hasler-Lewis CM, et al, Mushrooms and Health Summit Proceedings. *J Nutr*. 144(7), p.1128S–1136S. 2014.
11. Aida FMNA, Shuaimi M, Yazid M, Maaruf AF. Mushroom as a potential source of prebiotics : a review. *Trends Food Sci Tech*, 20(11–12), pp.567–575. 2009
12. Oso BA. Pleurotus tuber-regium from Nigeria. *Mycologia*. 69(2), pp.271–279. 1977.
13. Kabir Y & Kimura S. Dietary Mushrooms Reduce Blood Pressure in Spontaneously Hypertensive Rats ( SHR ). *J Nutr Sci Vitaminol*, 35, pp.91–94. 1989.
14. Akinlabi GA, Igbini VE, Akpaja EO, Iyawe VI. Preliminary Study on The Effect of Medicinal Mushroom Extract and Timolol Maleate on Dexamethasone Induced Ocular Hypertension in Feline's Eye Model. *JMBR*: 7, pp.2–7. 2008.
15. Suzuki R. Ocular Outflow Facility with Emphasis on Neuronal Regulation of Intraocular Smooth Muscles. *J Smooth Muscle Res*. 32: 229-247. 1996.
16. Akinlabi GA, Asowata OE, Ozolua R, Iyawe V. Contractile Effect of Aqueous Pleurotus tuberregium Extract on the Isolated Bovine Iris. *Current Eye Research*, 38:..1–5. 2013.