

NISEB 2010040/11106

Effect of a Polyherbal Mixture on Acetaminophen induced Hepato-nephro Toxicity in Rats

O. Iroanya¹, J. Okpuzor^{*1} and S. Akindele²

¹Department of Cell Biology and Genetics, University of Lagos, Akoka – Yaba, Lagos, Nigeria

²Department of Biochemistry, Nigerian Institute of Medical Research, Yaba, Lagos, Nigeria

(Received August 9, 2010; Accepted November 11, 2010)

ABSTRACT: **Aim of study:** A polyherbal formulation prepared from a mixture of leaves of *Gongronema latifolia*, *Ocimum gratissimum* and *Vernonia amygdalina* (GOV) was evaluated for hepato-nephro protective properties against acetaminophen-induced hepatic and renal toxicity in Wistar albino rats. **Materials and methods:** Normal wistar albino rats were orally treated with different doses of GOV extract (2000, 4000 and 8000 mg kg⁻¹ b. wt) and some standard hepatoprotective drugs such as Liv 52, Megasilymarin with isosilybin B, milk thistle extract and silymarin for 14 days. However, a day prior to the 14th day, a dose of Acetaminophen (APAP) 3 g kg⁻¹ body weight was administered p.o. 1h before GOV and the standard drugs to induce hepatic and renal damage. Two control experiments were setup which included normal rats treated with acetaminophen and normal rats that received only distilled water. The serum levels of Alkaline phosphatase, Alanine amino transferase, Aspartate amino transferase, Gamma-glutamyl transferase, Lactate dehydrogenase and biochemical analytes were monitored. **Results:** The results showed that rats treated with GOV exhibited significant (p< 0.05) decrease in serum levels of Alkaline phosphatase, Alanine amino transferase, Aspartate amino transferase, Gamma-glutamyl transferase, Lactate dehydrogenase, Cholesterol, Triglycerides, Urea and a subsequent increase in Albumin, Creatine and Total protein when compared to the toxin control group. **Conclusion:** The data from this study suggest that the polyherbal formulation possesses hepato and nephroprotective potential against Acetaminophen induced hepatotoxicity in rats. This provides scientific rationale for its use in traditional medicine for the treatment of liver diseases.

Keywords: Polyherbal formulation, *Gongonema latifolia*, *Ocimum gratissimum*, *Vernonia amygdalina*, liver and kidney diseases.

Introduction

The leaves of *Gongronema latifolia*, *Ocimum gratissimum* and *Vernonia amygdalina* locally known as Utazi, Onugbu and Nchanwu are widely used for food and medicinal purposes in South Eastern Nigeria. *Gongronema latifolia* belonging to the family of Asclepiadaceae is a climber while *Ocimum gratissimum* (Lamiaceae family) and *Vernonia amygdalina* (Asteraceae family) are shrubs. Their leaves are ethno medically believed to be effective for the treatment of diabetes, dysentery, gastrointestinal disorders and fever. They are also used for culinary purposes such that soups prepared with these leaves either in combination or individually, are believed to improve lactation. Traditional medicine practitioners claim that they provide a cure for hepatitis. *Gongronema latifolia* and *Vernonia amygdalina* have been reported to be useful in food and feed formulations as well as raw materials for industry (Eleyinmi et al, 2008). Ilori et al (1996) reported on the anti-diarrheal properties of *Ocimum gratissimum* and its essential oil exert antimicrobial activities (Ngassoum et al, 2003).

*To whom correspondence should be addressed.

The topical application of the essential oil of *Ocimum gratissimum* is also reported to reduce the biting ability of *Simulium damnosum* (blackflies) by about ninety percent (Usip *et al.*, 2006). The bitter principle from *Vernonia amygdalina* reported to be Vernonioside B₁ and its aglycones is believed to be the bioactive principle used to treat Chimpanzee suffering from gastro intestinal infection by *Ternidens* spp (Huffman *et al.*, 1993). Some other bioactive constituents have also been isolated from *Vernonia amygdalina*. The vernolides from *Vernonia amygdalina* exhibited high activity against *Penicillium notatum*, *Aspergillus flavus*, *Aspergillus niger* and *Mucor hiemalis*, respectively, while vernodalol showed moderate inhibitions against *Aspergillus flavus*, *Penicillium notatum* and *Aspergillus niger* (Erasto *et al.*, 2006). *Gongronema latifolia* is among the plants reported to be good sources of therapeutic agents in the treatment of Leishmaniasis (Carvalho and Ferreira, 2001; Rocha *et al.*, 2005).

On the other hand, Acetaminophen is one of the most common medications found in households. It is one of the most common sources of pharmaceutical products poisoning and account for most drug overdoses in Australia, New Zealand, the United Kingdom, and the United States (Daly *et al.*, 2008; Khashab *et al.*, 2007; Hawkins and Edwards, 2007; Larson *et al.*, 2005). It is primarily metabolized by glucuronidation, sulfation and N-hydroxylation and followed by conjugation with glutathione (Hendrickson and Bizovi, 2006 and Borne, 1995). Following overdose, this detoxification pathway becomes saturated and consequently NAPQI accumulates causing liver damage. Liver disease is often reflected by biochemical abnormalities of one of the two different hepatic systems or of liver function.

Materials and Methods

Plant materials

The leaves of *Gongronema latifolia*, *Ocimum gratissimum* and *Vernonia amygdalina* were purchased from Oyingbo market in Lagos Nigeria. Identification and authentication was done at the Department of Pharmacognosy, College of Medicine of the University of Lagos, Nigeria and voucher specimen (PCGH 444, PCGH 443 and PCGH 432) of *Gongronema latifolia*, *Ocimum gratissimum* and *Vernonia amygdalina* respectively deposited.

Preparations of polyherbal extract (GOV)

Twelve kilograms of each of the fresh leaves of *Gongronema latifolia*, *Ocimum gratissimum* and *Vernonia amygdalina* were blended with five liters (5L) of ethanol (50% v/v), decanted and filtered. The filtrate was evaporated to dryness using an oven set at 40°C. The dried extract was weighed and reconstituted in distilled water to give a concentration of 100 mg ml⁻¹.

Drugs and Chemicals

LIV 52 syrup (Himalaya Drug company, India), Megasilymarin with Isosilybin B (Life Extension, Florida), Milk Thistle liquid extract (Swanson, USA.), Silymarin (Sigma, USA), Ethanol (Sigma, USA), Acetaminophen (APAP) (Emzor Pharmaceuticals, Nigeria), all biochemical tests (Albumin (ALB), Alkaline phosphatase (ALP), Alanine Aminotransferase (ALT), Aspartate Aminotransferase (AST), Cholesterol (CHO), Creatinine (CREA), total protein (TP), triglycerides (TG), Lactate dehydrogenase (LDH), Gamma-glutamyl transferase (GGT) and Urea) were assayed using Randox kits.

Animals

Sixty-three (63) wistar albino rats weighing between 120 – 160 g and hundred (100) albino mice (20-25 g) weight of either sex were obtained from the Laboratory Animal Centre of the College of Medicine, University of Lagos, Nigeria. The animals were left for 10 days to acclimatize under controlled environmental conditions with drinking water and standard diet given *ad libitum*. This study was conducted according to the rules and regulations of The University of Lagos Ethical Committee on experimental use of animals.

Acute Toxicity

According to the Organization of Economic Cooperation and Development (OECD) guidelines for testing of chemicals five groups of 10 mice each were treated with different doses of the extract (1, 2, 4, 8 and 16 g kg⁻¹ body weight) orally while another five groups were intraperitoneally (i.p) administered with 500, 1000, 1500, 2000 and 2500 mg kg⁻¹ doses of the extract. The control groups consisting of ten mice received 10ml kg⁻¹ distilled water. The animals were observed continuously for 24h for behavioral changes and mortality.

Acetaminophen (APAP) Induced Hepatotoxicity in Rats

Wistar Albino rats of either sex were randomly selected and assigned into nine groups of seven animals each. Each group of rats received varied treatment for 14 days.

Animals in group 1 (normal control) were treated with distilled water, 10 ml kg⁻¹ body weight p.o. while the toxin control animals (group 2) received distilled water 10 ml kg⁻¹ body weight for fourteen days and APAP (3 g kg⁻¹ body weight) in distilled water on the thirteenth day only.

The extract was administered 1hr before APAP (3 g kg⁻¹ body weight in distilled water p.o.) administration on the thirteenth day.

The test animals in groups 3-5 were treated with 2000, 4000 and 8000 mg kg⁻¹ body weight of polyherbal extract (GOV) respectively for fourteen days. On the thirteenth day, GOV was administered 1hr before treatment with APAP 3 g kg⁻¹ body weight in distilled water p.o.

Animals in group 6, 7, 8 and 9 received LIV 52 syrup (300 mg kg⁻¹ body weight), Megasilymarin with Isosilybin B (300 mg kg⁻¹ body weight in distilled water) Milk Thistle liquid extract (300 mg kg⁻¹ body weight) and Silymarin (300 mg kg⁻¹ body weight in distilled water) p.o. respectively for fourteen days. On the thirteenth day, the drugs were administered 1hr before treatment p.o. with APAP 3 g kg⁻¹ body weight in distilled water.

Biochemical and histological studies

Forty eight hours after APAP intoxication, the animals were anesthetized mildly with ether and blood was collected from the retro-orbital plexus. They were sacrificed and more blood samples were collected by cardiac puncture for evaluating the biochemical parameters. Heart, Liver and Kidney were carefully harvested and preserved in 10% normal saline for histological studies.

The Blood cholesterol (CHO) (Roeschlau *et. al.*, 1974), total protein (TP) (Weichselbaum, 1946), Albumin (ALB) (Dumas *et. al.* 1971), Creatinine (CREA) (Bartels *et. al.*, 1972), Alanine Aminotransferase (ALT), Aspartate Aminotransferase (AST) (Reitman and Frankel, 1957), Alkaline phosphatase (ALP), triglyceride (TG) (Teitz, 1990), Lactate dehydrogenase (LDH) (Rec. GSKC (DGKC), 1970 and 1972), Gamma-glutamyl transferase (GGT) (Szasz, 1969) and Urea (Kassirer, 1971 and Teitz, 1970) were assayed according to the instructions on Randox kits manual.

The Heart, Liver and Kidney samples were fixed in 10% formal saline. The tissues were processed and 3 micrometers thick paraffin sections of buffered formalin-fixed tissue samples were stained with heamatoxylin and eosin for photomicroscopic observations of the histological architecture of the control and treated rats. The histological architecture of the organs of the control group (group 1) was compared with those of the treated rats (groups 2-9).

Statistical analysis

The results were expressed as mean \pm SEM. Statistical analysis of the data was performed using ANOVA statistical SPSS package (15.0) version. The significance of differences among all groups was determined by the Tukey HSD test. P-values less than 0.05 ($P \leq 0.05$) were considered to be statistically significant.

Results

Acute Toxicity

Oral administration of the extract up to 16000 mg kg⁻¹ did not result in deleterious effect or mortality 24h after and within seven days post-dosing irrespective of the extract dose tested.

Biochemical analysis

The rats treated with APAP alone (group 2) developed significant nephro-hepatocellular damage as evidenced from the increase in serum levels of ALT, ALP, AST, creatinine, GGT, LDH, urea and triglycerides (Table 1a & b) and decrease in total protein and albumin when compared to the control group (Group 1). Pretreatment with the polyherbal extract GOV at 2000, 4000 and 8000 mg kg⁻¹, LIV 52 syrup, Milk thistle extract, Megasilymarin with isosilybin B and silymarin (groups 3, 4, 5, 6, 7, 8 and 9 respectively), caused significant ($p < 0.05$) decrease in ALP, ALT, AST, Creatinine, LDH, GGT and Urea level when compared to the APAP control group (group 2) thereby protecting the liver and kidney against APAP induced hepatotoxicity. Albumin activity in Groups 4, 7 and 9 were significantly ($p < 0.05$) increased compared to the toxin control group (group 2). A significant ($p < 0.05$) increase in ALP activity in Groups 2, 3 and 5 compared to the control group (group 1) was observed, while ALT and AST activities in groups 2, 3, 4, 5, 6 and 7 were significantly ($p < 0.05$) higher than the control group. Only in the toxin control group (group 2) was significant ($p < 0.05$) increase in creatinine, LDH, Cholesterol, triglycerides and urea activity observed compared to the control group.

The pattern of results obtained from histological studies corroborates biochemical results obtained from each group of experimental animals.

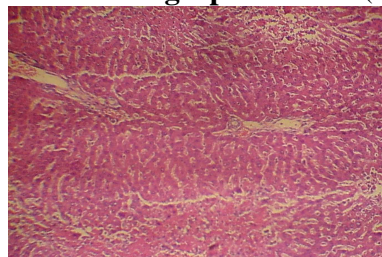
The liver of rats in the toxin control group 2 (photomicrograph 2) showed vacuolization of hepatocytes, sinusoidal dilation and centrilobular hepatic necrosis compared to control group (photomicrograph 1). Additionally, it showed severe steatohepatitis with marked neutrophilic activity and periportal mixed necro-inflammatory cells, infiltrated with lymphocytes and Kupffer cells.

Administration of the different doses of GOV did not show diffuse microvesicular steatosis (photomicrograph 3-5). However, there was minimal periportal lymphocytic infiltration with necrosis at different concentrations of the extract compared to the toxin group. The morphology of the liver of rats in Liv 52, milk thistle extract, Megasilymarin and silymarin groups were normal.

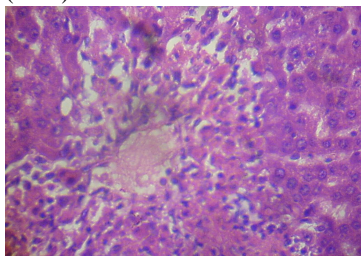
Furthermore, the Kidney (photomicrograph 7) of APAP treated rats showed hemorrhage vacuolization, tissue oedema with few dilated blood filled vessels, tubular degeneration and necrosis while the kidney of the control rats (photomicrograph 6) showed normal renal glomeruli and tubules. The kidney of animals in groups 3-9 showed almost normal renal glomeruli and tubules comparable to the control (photomicrograph 8-10).

Albumin levels in all the groups were not significant ($p < 0.05$) when compared to the control group while groups 4, 7 and 9 showed significantly ($p < 0.05$) higher albumin levels when compared to APAP control group. ALP activities in groups 2, 3 and 5 were significantly ($p < 0.05$) high when compared with the normal control group while all the groups were significantly ($p < 0.05$) lower than the APAP control group.

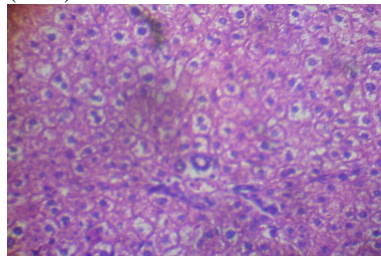
Photomicrograph 1:Control (liver)



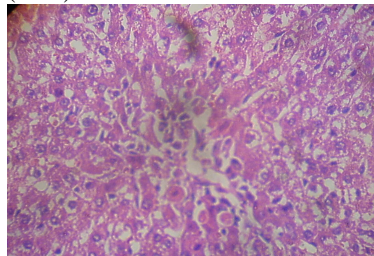
Photomicrograph 2:Distilled water + APAP (liver)



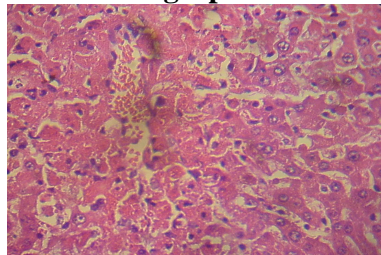
Photomicrograph 3: GOV 2000mg/kg + APAP (liver)



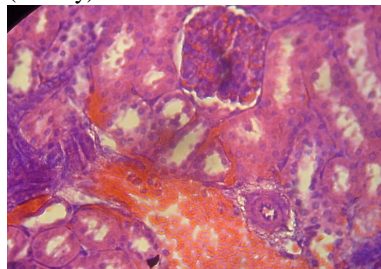
Photomicrograph 4: GOV 4000mg/kg + APAP (liver)



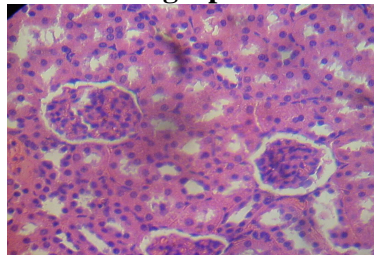
Photomicrograph 5: Liv. 52 + APAP (liver)



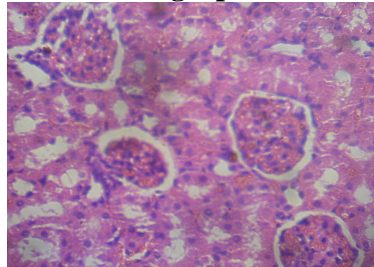
Photomicrograph 7: Distilled water + APAP (kidney)



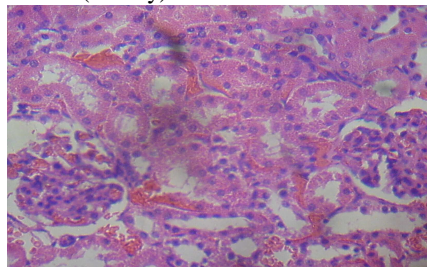
Photomicrograph 6: Distilled water (kidney)



Photomicrograph 8: Liv 52 + APAP (kidney)



Photomicrograph 9: GOV (4000mg kg⁻¹) + APAP (kidney)



Photomicrograph 10: GOV (8000mg kg⁻¹) + APAP (kidney)

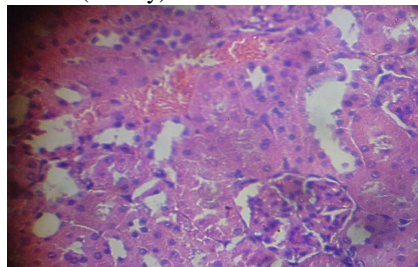


Table 1a: Serum ALT, AST, ALP, LDH and GGT activities in rats fed GOV by intragastral gavage after administration of APAP.

	ALT (U/L)	AST (U/L)	ALP (U/L)	LDH (U/L)	GGT (U/L)
Negative Control	24.2±1.2 ^(b)	10.3±1.0 ^(b)	70.0±6.5 ^(b)	14.0±1.4 ^(b)	1254.7±84.6 ^(b)
Toxin Control	95.9±2.2 ^(a)	77.8±2.1 ^(a)	447.0±11.5 ^(a)	56.5±3.5 ^(a)	3920.0±421.1 ^(a)
2000mg/kg (GOV+APAP)	45.4±4.4 ^(a, b)	18.8±1.5 ^(a, b)	165.6±16.1 ^(a, b)	19.7±3.6 ^(b)	1584.0±57.5 ^(b)
4000mg/kg (GOV+APAP)	65.1±4.7 ^(a, b)	16.8±1.0 ^(a, b)	16.9±23.1 ^(b)	13.5±0.6 ^(b)	2611.9±95.8 ^(a, b)
8000mg/kg (GOV+APAP)	75.7±5.1 ^(a, b)	21.2±0.8 ^(a, b)	131.1±8.4 ^(a, b)	10.7±0.4 ^(b)	2518.3±81.6 ^(a, b)
300mg/kg (LIV 52 + APAP)	47.8±3.8 ^(a, b)	16.5±1.67 ^(a, b)	93.2±7.3 ^(b)	18.4±2.56 ^(b)	1719.9±214.2 ^(b)
300mg/kg (Megasil + APAP)	49.8±1.24 ^(a, b)	19.3±1.2 ^(a, b)	109.6±5.6 ^(b)	14.6±1.4 ^(b)	2018.1±174.1 ^(b)
300mg/kg (Milk Thistle + APAP)	35.0±2.8 ^(b)	13.8±1.1 ^(b)	88.6±4.4 ^(b)	15.8±1.4 ^(b)	1983.6±147.5 ^(b)
300mg/kg (Silym + APAP)	28.3±3.7 ^(b)	11.1±0.4 ^(b)	110.1±5.3 ^(b)	10.1±1.8 ^(b)	1420.6±65.5 ^(b)

Values are expressed as mean ± SEM for seven rats. The mean difference is significant at the 0.05 level. (a) = p < 0.05 as compared with the normal control group. (b) = p < 0.05 as compared to APAP control group. The significance of differences among all groups was determined by the Tukey HSD test.

Table 1b: Serum ALT, AST, ALP, LDH and GGT activities in rats fed GOV by intragastral gavage after administration of APAP.

	ALB (g/L)	CHOL (mmol/L)	CREAT (mmol/L)	TP (g/L))	TG (mmol/L)	UREA (mmol/L)
Negative Control	34.3±1.9	1.7±0.1 ^(b)	63.9±1.5 ^(b)	112.8±12.5 ^(b)	1.5±0.1 ^(b)	6.4±0.4 ^(b)
Toxin Control	28.9±1.9	3.0±0.1 ^(a)	89.8±3.5 ^(a)	56.2±1.9 ^(a)	2.9±0.2 ^(a)	13.6±0.7 ^(a)
2000mg/kg (GOV+APAP)	35.1±0.8	2.3±0.1	70.0±3.1 ^(b)	71.7±6.1 ^(a)	1.9±0.2 ^(b)	7.5±0.3 ^(b)
4000mg/kg (GOV+APAP)	42.4±2.2 ^(b)	1.9±0.2 ^(b)	70.5±2.9 ^(b)	74.9±3.3 ^(a)	1.5±0.1 ^(b)	5.9±0.1 ^(b)
8000mg/kg (GOV+APAP)	34.7±2.9	2.3±0.2	67.2±3.1 ^(b)	73.0±2.9 ^(a)	1.5±0.3 ^(b)	6.1±0.5 ^(b)
300mg/kg (LIV 52 + APAP)	38.2±1.9	2.0±0.1 ^(b)	60.7±4.0 ^(b)	79.6±5.0 ^(a, b)	2.0±0.2 ^(b)	6.3±0.3 ^(b)
300mg/kg (Megasil + APAP)	38.6±1.5 ^(b)	2.0±0.1 ^(b)	64.6±3.0 ^(b)	81.2±4.3 ^(a, b)	1.5±0.2 ^(b)	6.1±0.4 ^(b)
300mg/kg (Milk Thistle + APAP)	34.7±2.9	1.7±0.2 ^(b)	61.9±3.9 ^(b)	80.7±3.7 ^(a, b)	1.6±0.1 ^(b)	6.2±0.4 ^(b)
300mg/kg (Silym + APAP)	38.8±1.7 ^(b)	2.2±0.1 ^(b)	62.2±2.6 ^(b)	79.9±3.9 ^(a, b)	1.4±0.09 ^(b)	6.2±0.1 ^(b)

Values are expressed as mean ± SEM for seven rats. The mean difference is significant at the 0.05 level. **(a)** = $p < 0.05$ as compared with the normal control group. **(b)** = $p < 0.05$ as compared to APAP control group. The significance of differences among all groups was determined by the Tukey HSD test.

Discussion

Results obtained from this study indicated that APAP induced severe liver and kidney damage as observed in the serum levels of ALP, ALT, AST, CREA, GGT, LDH, TG, Urea and decrease in ALB and TP. This elevation can be attributed to the release of enzymes from the cytoplasm into the blood circulation after rupture of the plasma membrane and cellular damage. One of the hallmark signs of hepatic injury is apparent leakage of cellular enzymes into the blood stream and this is associated with massive necrosis of the liver (Shyamal *et al.*, 2006).

ALP, ALT and AST are commonly used as marker enzymes in assessing APAP induced hepatotoxicity (Yen *et al.*, 2007). ALT and AST are exquisitely sensitive indicators of hepatocellular injury and provide the best guide to hepatocellular necrosis inflammation though, ALT is more specific for determining hepatocellular damage (Shyamal *et al.*, 2006). Alkaline phosphatase (ALP) is an enzyme in the cells lining the biliary ducts of the liver. ALP levels in plasma will rise with large bile duct obstruction, intrahepatic cholestasis or infiltrative diseases of the liver. In cases of injury to the liver whether acute or chronic, an increase in serum concentration of aminotransferases are observed (Giannini *et al.*, 2005).

It is likely that prior administration of GOV which lowered the biochemical indices in this study may have done so either by increasing the rate of their clearance from the system or reduced enzyme synthesis hence preventing accumulation. If the bile duct is inflamed or damaged, GGT and ALP can get backed up and spill out from the liver into the bloodstream (Giannini *et al.*, 2001), while Albumin levels are decreased in chronic liver disease, such as cirrhosis. The prophylactic action of GOV by increasing albumin and total protein levels could be by inducing increased protein synthesis consequently leading to generation of new cells to replace cells damaged due to APAP toxicity. Albumin level is also decreased in nephrotic syndrome, where it is lost through the urine. Very low levels of albumin and elevated levels of LDH may be a sign of liver damage. In renal diseases, the rate of serum urea production exceeds the rate of clearance leading to serum urea accumulation (Mayne, 1994). A high value of blood urea nitrogen (BUN) can indicate kidney injury or disease, or be caused by some medications. An elevation in creatinine and Urea levels is an index of nephrotoxicity (Ali *et al.*, 2001) while low creatinine levels can indicate a decrease in muscle mass or severe liver disease and this is not the case with GOV extract.

The biochemical results corroborated that obtained from histological studies of the liver and kidney sections. Therefore, GOV may have hepato and nephroprotective effects against APAP induced toxicity giving an insight on the potential use of this polyherbal mixture as a hepato and nephroprotective agent. Further studies are however required to elucidate its hepato and nephroprotective mechanisms, isolate the specific bioactive components responsible for the hepato and nephroprotective action and establish its mechanism of action.

References

1. Bartels, H., Bohmer, M., and Heierli, C. (1972). Serum creatinine determination without protein precipitation. *Clin Chim Acta* **37**:193-7.
2. Borne, R.F. (1995). "Nonsteroidal Anti-inflammatory Drugs" In *Principles of Medicinal Chemistry*, Fourth Edition. Eds. Foye, William, O; Lemke, Thomas L; Williams David A. Published by Williams & Wilkins, p 544-545.
3. Daly, F.F., Foutain, J.S., Murray, L., Graudins, A and Buckley, N.A (2008). Guidelines for the management of paracetamol poisoning in Australia and New Zealand—explanation and elaboration. A consensus statement from clinical toxicologists consulting to the Australasian poisons information centers. *Med. J. Aust.* **188** (5): 296-301.
4. Dong, H., Haining, R.L., Thummel, K.E., Rettie, A.E and Nelson, S.D (2000). Involvement of human cytochrome P450 2D6 in the bioactivation of acetaminophen. *Drug Metab Dispos.* **28**(12): 1397-400
5. Dumas, B.T., Watson, W.A and Briggs, H.G (1971). Albumin standards and measurements of serum albumin with bromocresol green. *Clin Chim Acta* **31**:87-96.
6. Hawkins, L.C., Edwards, J.N and Dardan, P.I (2007). Impact of restricting paracetamol pack sizes on paracetamol poisoning in the United Kingdom: A review of the literature. *Drug Saf* **30**(6): 465-479.
7. Hendrickson, R.G and Bizovi, K. E (2006). "Acetaminophen" in Nelson, Lewis H., Flomenbaum, Neal., Goldfrank, Lewis R *et al.* Goldfrank's toxicologic emergencies, p.525, New York: McGraw-Hill.
8. Kassirer, J. P. (1971). Clinical evaluation of kidney function - glomerular function. *N Engl J Med* **285**: 385-389.
9. Khashab, M., Tector, A.J and Kwo, P.Y (2007). Epidemiology of acute liver failure. *Curr Gastroenterol Rep* **9** (1): 66-73.
10. Larson, A.M., Polson, J., Fontana, R.J., Davern, T.J., Lalani, E., Hynan, L.S., Reisch, J.S., Schiodt, F.V., Ostapowicz, G., Shakil, A.O and Lee, W.M (2005). Acetaminophen-induced acute liver failure: results of a United states multicenter, prospective study. *Hepatology* **42**(6): 1364-72.
11. Lee, S.S.T., Buter, J. T. M., Pineau, T., Fernandez-Salguero, P., and Gonzalez, F. J. (1996) Role of CYP2E1 in the hepatotoxicity of acetaminophen. *J Biol Chem* **271**: 12063-12067.

12. Lui, G. T. (1989). Pharmacological actions and Clinical use of Fructus shizandrea. *Journal of Chinese Medicine* **102**, 740-749.
13. Makin A, Williams R. (1994). The current management of paracetamol overdosage. *Br J Clin Pharmacol*; **48**:144–8.
14. Rec, G.S.C.C (1970). Determination of α -hydroxybutyrate dehydrogenase (α -HBDH) activity in serum. DGKC method, *J. Clin. Chem. Clin. Biochem.* **8**: 658.
15. Rec. G.S.C.C. (DGKC) (1972). Optimised standard colorimetric methods. *J Clin. Chem Clin Biochem* **10**:182.
16. Reitman S and Frankel S. (1957). A colorimetric method for the determination of serum glutamic oxalacetic and glutamic pyruvic transaminases. *Amer. J. Clin. Pathol.* **28**: 56-63.
17. Roeschlau, P., Bernt, E. and Gruber, W. (1974).Enzymatic determination of total cholesterol in serum. *Z Klin. Chem. Klin. Biochem* **12**: 403-407.
18. Schiodt, F. V., Rochling, F. A., Casey, D. L., and Lee, W. M. (1997). Acetaminophen toxicity in an urban county hospital. *N Engl J Med* **337**: 1112-1117.
19. Szasz G. (1969). A kinetic photometric method for serum gamma-glutamyl transpeptidase. *Clin Chem*; **22**: 124-136.
20. Teitz, N.W. (1970). *Fundamentals of Clinical Chemistry* W.B. Saunders Company, Philadelphia.
21. Tietz N.W. (1990). *Clinical Guide to Laboratory Tests*, Second Edition W.B. Saunders Company, Philadelphia, USA 554-556
22. Vermeulen, N. P. E., Bessems, J. G. M., and Vandestraat, R. (1992) Molecular aspects of paracetamol-induced hepatotoxicity and its mechanism-based prevention. *Drug Metab Rev* **24**: 367-407.
23. Weichselbaum, T. E. (1946). Estimation of serum total protein by Biuret method. *Am J Clin. Path.* **16**: 40-48.